




Fetal Pig Words To Know

Characteristics & External

- age of your pig
- sex of your pig
- anterior/cranial section
- posterior/caudal section
- dorsal/superior section
- ventral/inferior section
- lateral section
- medial section
- epitrichium
- mouth
- lips
- tongue
- snout
- external nares
- eyes
- nictitating membrane
- external acoustic meatus
- pinna/auricle
- trunk
- thorax
- abdomen
- mammary papillae
- umbilical cord
- umbilical arteries
- umbilical vein
- allantoic stalk
- genital papillae
- scrotal sac
- anus
- wrist
- elbow
- knee
- ankle
- hoof



Skeletal System

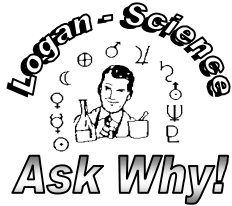- parietal auditory meatus
- zygomatic arch
- orbit
- nasal
- maxilla
- premaxilla
- mandible
- canine teeth
- mental foramen
- auditory bulla
- skull/ cranium
- atlas
- axis
- vertebral column
- scapula
- rib
- pelvis
- ilium
- ischium
- femur
- patella
- tibia
- fibula
- calcaneus
- tarsals
- metatarsals
- phalanges
- humerus
- radius
- ulna
- carpals
- metacarpals

Muscular System

- origin
- insertion
- muscle body
- gastrocnemius
- Achilles tendon
- biceps femoris

Digestive system

- hairy papilla
- ductus venosus
- urinary bladder
- diaphragm
- parotid gland
- Stensen's duct
- submandibular gland
- sublingual gland
- lymph node
- masseter
- epiglottis
- vestibule
- oral cavity
- tongue papillae
- hard palate
- soft palate
- oropharynx
- nasopharynx
- laryngopharynx
- esophagus
- liver
- gall bladder
- cystic duct
- hepatic duct
- common bile duct
- lesser omentum
- stomach
- duodenum
- meconium
- gastric mucosa
- cardiac sphincter
- diverticulum
- pyloric sphincter
- small intestine
- villa
- spleen
- greater omentum
- pancreas
- large intestine
- spiral colon
- rectum
- peritoneum
- mesentery



Fetal Pig Words To Know

Respiratory System

- trachea
- vocal folds (cords)
- hyoid bone
- thymus gland
- thyroid gland
- larynx
- common carotid arteries
- internal jugular veins
- external jugular veins
- vagus nerve
- inferior laryngeal nerves
- pleural cavity
- pericardial sac
- heart
- pleura
- parietal pleura
- pericardium
- axillary vein
- coronary arteries
- rib
- intercostal muscles
- hemiazygos vein
- apical lobes of lungs
- cardiac lobes of lungs
- intermediate lobes
- right main bronchus
- left main bronchus
- apical bronchus
- phrenic nerve
- diaphragm



Circulatory System

- pericardium
- epicardium
- apex of the heart
- left ventricle of heart
- anterior longitudinal sulcus
- right ventricle of heart
- coronary sulcus
- right atrium of heart
- left atrium of heart
- vagus nerve
- internal jugular veins
- common carotid arteries
- external jugular veins
- anterior vena cava
- brachiocephalic veins
- subscapular veins
- subclavian veins
- axillary vein
- brachial vein
- pulmonary arteries
- pulmonary veins
- aortic arch
- aorta
- ductus arteriosus
- internal mammary vein
- internal mammary artery
- celiac artery
- anterior mesenteric artery
- posterior mesenteric artery
- external iliac arteries
- femoral arteries
- internal iliac arteries
- umbilical arteries
- common iliac veins
- posterior vena cava
- kidney
- renal veins
- renal arteries

Reproductive System

Female Fetal Pig

- ovaries
- uterine tubes (fallopian)
- ostium
- uterine horns (cornua)
- urethra
- ureter
- vagina
- urogenital sinus (vulva)
- genital papillae
- labia
- urinary bladder
- pubis
- rectum
- anus

Male Fetal Pig

- scrotum
- inguinal canals
- processus vaginalis
- testes
- epididymis
- gubernaculum
- vas deferens
- penis
- urethra
- ureter
- Cowper's gland (bulbourethral)
- pubis
- testicular artery
- urinary bladder
- rectum
- urinary bladder
- rectum
- anus

KNOW THE LOCATION AND THE FUNCTION OF EACH STRUCTURE