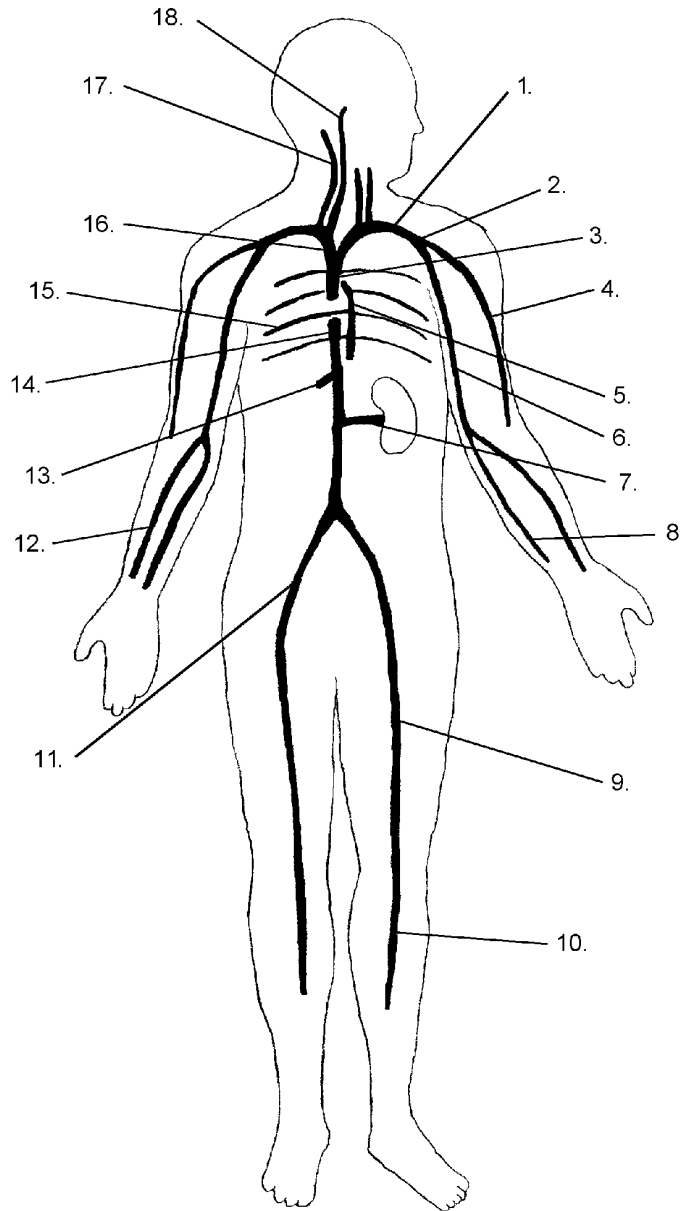


Procedure:

1. In the diagram below, label the appropriate veins. Use the following terms:

- | | | | | | |
|----------|------------------|---------|--------------------|------------|--------------------|
| axillary | brachiocephalic | femoral | inferior vena cava | radial | superior vena cava |
| azygous | cephalic | hepatic | intercostal | renal | tibial |
| brachial | external jugular | iliac | internal jugular | subclavian | ulnar |

The Venous System



2. In the diagram below, label the appropriate arteries. Use the following terms:

- | | | | | | |
|----------|-----------------|--------------|------------|---------------|-------|
| aorta | brachiocephalic | iliac | mesenteric | right carotid | ulnar |
| axillary | celiac | intercostal | radial | subclavian | |
| brachial | femoral | left carotid | renal | tibial | |

The Arterial System

